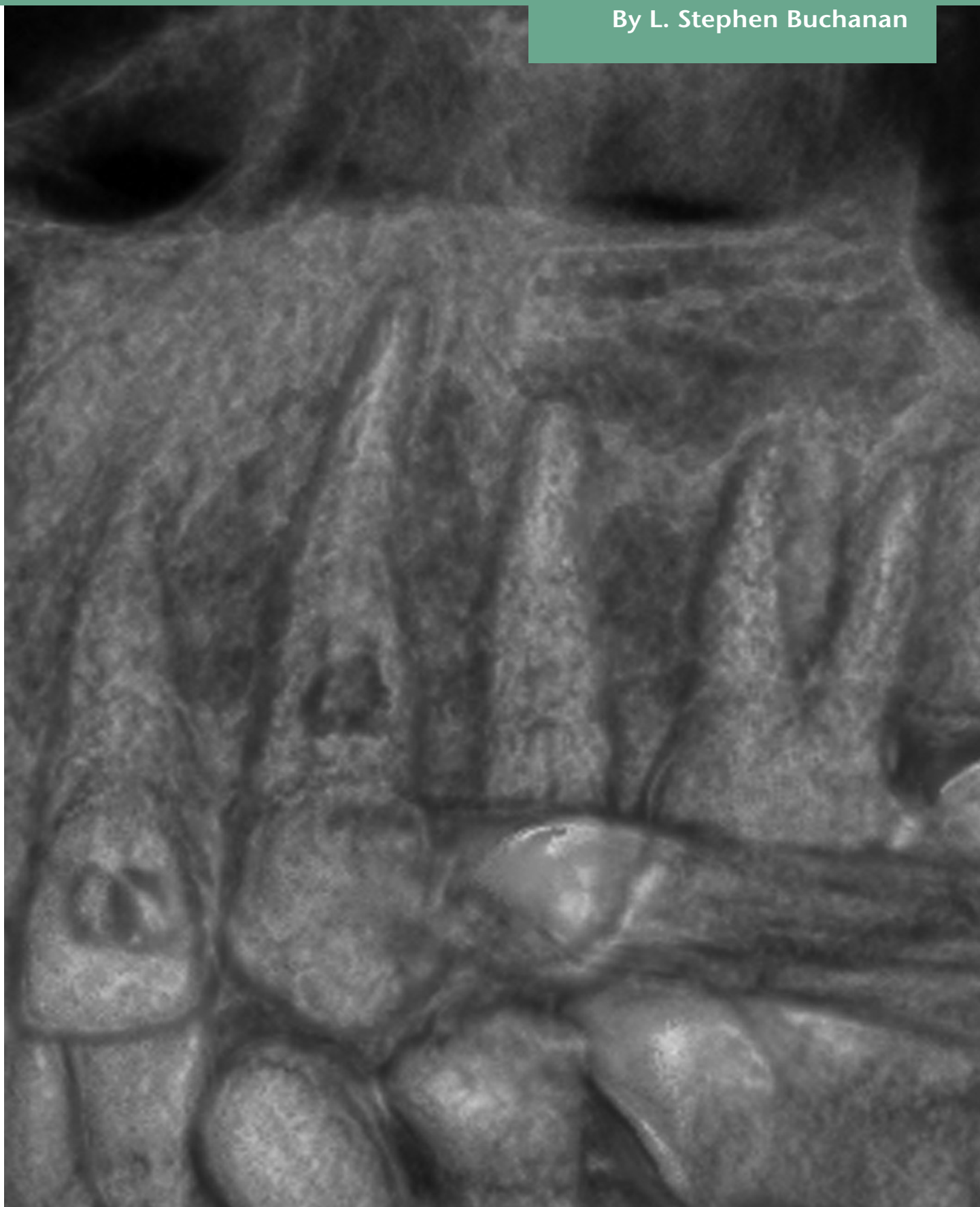


# The dawning of 3D endodontic practices

By L. Stephen Buchanan



# The dawning of 3D endodontic practices

## L. Stephen Buchanan takes a look at the benefits of introducing 3D imaging into the endodontic practice

Dr Herbert Schilder elevated the specialty of endodontics to its current level of accomplishment through his dogged insight (1967) that root canal anatomy is complex, and that our success in treating endodontic pathosis is directly proportional to our ability to treat it to its full apical and lateral extents. Bacteria and degenerating pulp tissue live in empty dead root canal spaces. Clean them out totally, obturate them, and the periradicular tissues will nearly all heal. It seems simplistic, but fundamental truths are like that.

The complexity of root canal anatomy has been understood since Walter Hess published his book on endodontic anatomy in 1925. Ironically, Hess's work contributed to the focal infection hysteria in that age as it suggested that we could not hope to adequately treat root canal systems and predictably eliminate them as continuing sources of infection in our patients bodies. Fortunately, those who came to understand the anatomic challenge of endodontic therapy, and who could envision methods to address those irregular spaces, laid the groundwork for treatment regimes that could deliver the outcomes that clinicians and patients expected when signing on for saving pulpally-involved teeth.

Hess's work with cleared teeth was followed much later by CT-reconstructed anatomic research (Buchanan, 1995; Brown, Herbranson, 2009) confirming and further informing us of the amazing anatomic realities of the spaces in which dental pulps form and contain endodontic pathoses after pulpal degeneration. While this anatomic research has confirmed what Walter Hess described earlier, it did not provide a direct solution, in terms of pre-operative imaging, for the practicing dentist. This promise has now been met with the introduction of high-resolution cone beam computed tomography (CBCT).

While CBCT has been available to dentistry for several years, its contribution to endodontic therapy has been limited by its relatively high X-ray exposure to patients and its low resolution-in terms of endodontic anatomy. If the detail seen in the CBCT imaging is low and the radiation absorbed by patients is high, the advantages of this imaging can only be used in special cases – difficult diagnostic cases for the most part. However, new technology has changed that paradigm significantly (Ziegler, Woertche, Brief, Hassfeld, 2002; Estrela, Bueno, Leles, Azevedo, Azevedo, 2008; Cohenca, Simon, Roges, Morag, Malfaz, 2007).

In my own practice, I chose the Accuitemo CBCT machine manufactured by J. Morita because it addresses the radiation hygiene issue. This machine has a smaller field of view (FOV) than all other dental CBCT machines.

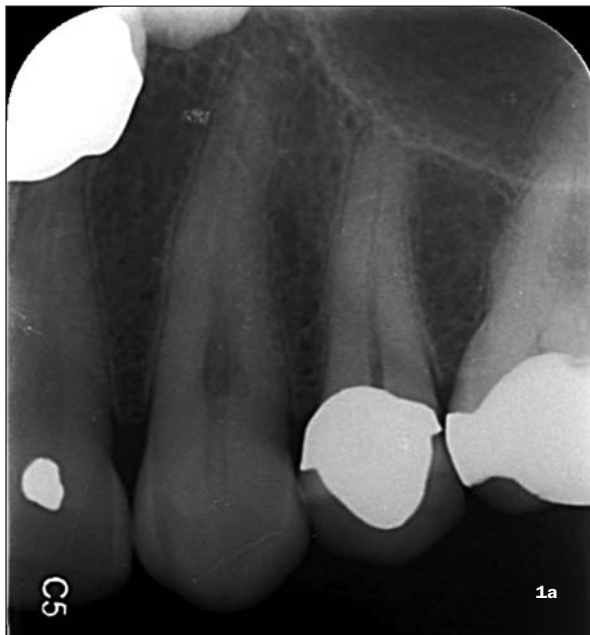Initially I thought that this was a deficit. As I considered the CBCT machines on the market, my first impression was that I wanted as large an FOV as I could get. Wow, I couldn't have been more wrong. I came to understand that a smaller FOV meant that the absorbed dose of radiation (8-12 mSevers) with this smaller FOV was exponentially smaller than those delivered with all of the other CBCT machines (absorbed radiation is a function of the FOV cubed). So, the fact that the FOV of the Accuitemo is a sextant of the patient's dentition instead of their whole mouth means that the absorbed radiation is something like one tenth as large as the rest of the CBCT exposures. 8-12 mSevers is about the amount of an analog panorex or 2-3 analog periapical X-ray films. What this means to me is that I can scan at will.

Beyond this, the remarkable resolution gained by the imaging technology inherent in this design delivers a result that has changed for me, literally, my practice of endodontics. When I realized I could see lateral canal anatomy before I entered the tooth, I knew that having a volumetric image before I cut an access cavity was something I wanted available to me on every case.

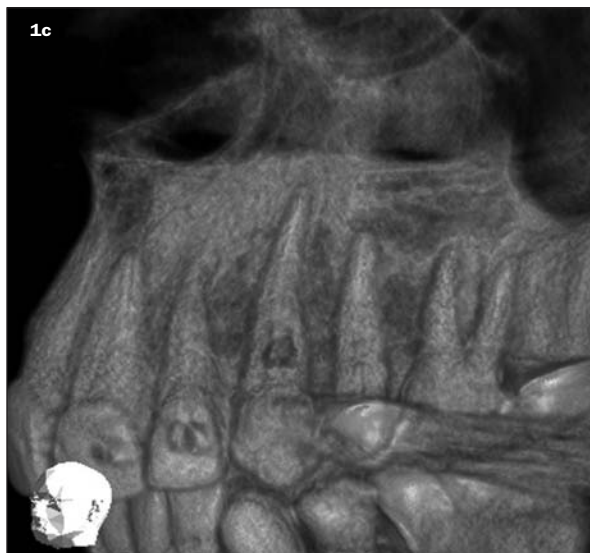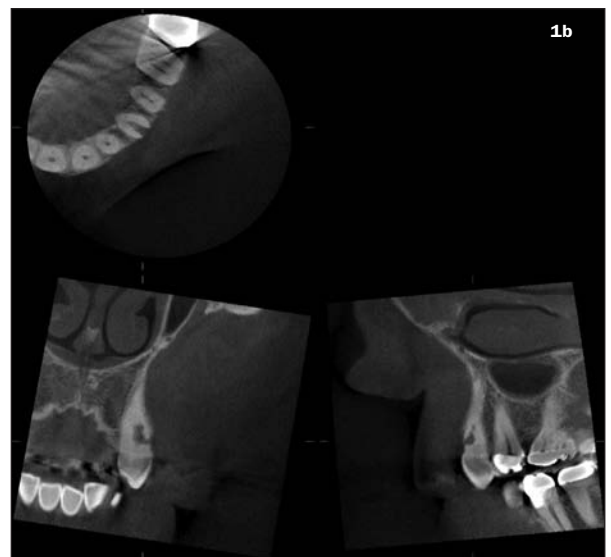While many of my peers may think this is unnecessary or even over-kill, the best way I can make this understood is to remind my fellow specialists of how we first thought of operating microscopes in endodontic practice. We thought they were going to help us just in difficult cases, such as surgery. It is still humbling to remember, but after the first blush most of us quickly understood that operating microscopes would improve virtually every part of our procedural experience. The advantage of CBCT imaging in an endodontic practice is no different. I know this is very bad news to my colleagues, in terms of potential capital expenditures, but I will tell you from experience that having a CBCT machine that can deliver this kind of anatomic imagery in your practice will change

**L. Stephen Buchanan, DDS, FICD, FACD is a diplomate of the American Board of Endodontics and an assistant clinical professor at the post-graduate endodontic programs at USC and UCLA. He maintains a private practice limited to endodontics and implant surgery in Santa Barbara, California and is the founder of Dental Education Laboratories, a hands-on training center serving general dentists and endodontist upgrading their skills in new endodontic and implant technology. Dr Buchanan can be reached through his website, [www.endobuchanan.com](http://www.endobuchanan.com).**

**Figure 1a:** The patient presented with pain to palpation over tooth #11. Vitality testing revealed that the tooth was vital. The conventional pre-operative radiograph showed an unusual appearance of the root canal space just apical to the CEJ. All periradicular bone appeared to be normal

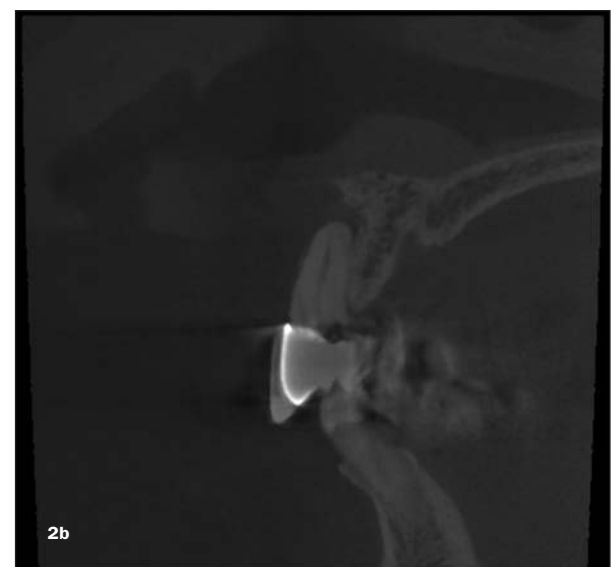
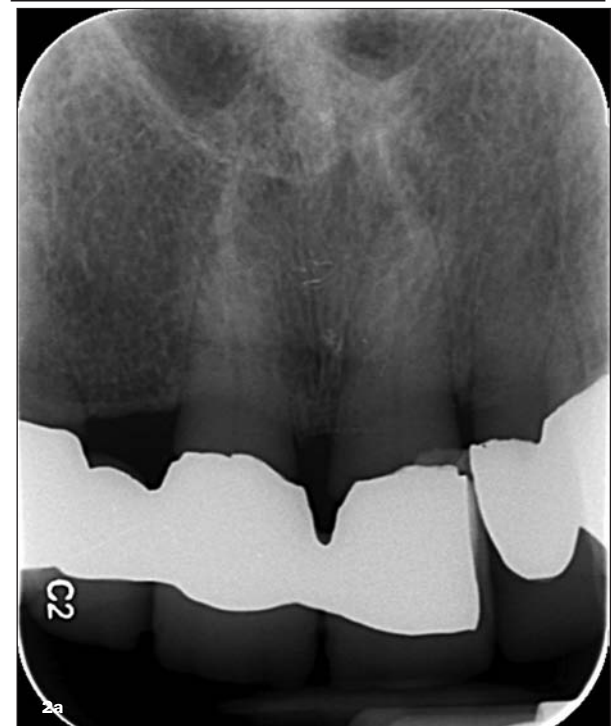

**Figures 1b and 1c:** CBCT imaging revealed a large internal/external resorption defect on the buccal surface of the root just above the osseous crest of bone, dictating extraction. Typically, treatment of this tooth would have been instituted, wasting the patient's time and money when the tooth was hopeless



**Figure 2a:** The patient presented with pain to palpation at the apex of tooth #9, it was non-responsive to vitality testing, yet an obvious lesion was not seen on the conventional periapical film

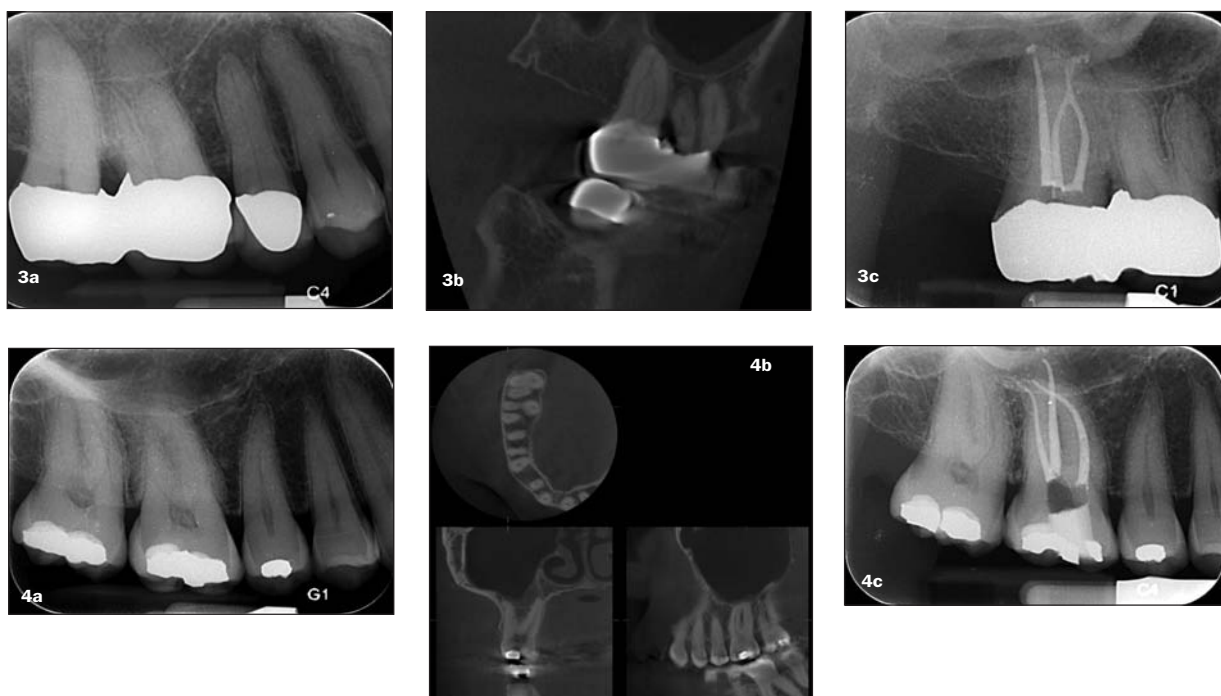
**Figure 2b:** The patient was CT scanned, revealing a large periapical lesion



your professional life. I know this is a strong statement, but before you dismiss it out of hand, let me just share a couple of cases and then you can decide.

The first cases are both from patients with teeth that would not have been easily diagnosed or treatment planned without having CT images – where CT images show resorption that was very indistinct or not seen at all on conventional 2D digital images (Figures 1a, 1b, 1c) or cases where periradicular lesions of endodontic origin are indistinct with 2D imagery but where high-resolution CT imaging showed them to be distinct and significant in size (Figures 2a and 2b). These are the cases that we can all agree are aided by volumetric viewpoints.

The paradigm shift for me was in the next class of cases, those that were easily diagnosed and treatment planned – those vanilla, routine teeth (Figures 3a, 3b, 3c, 4a, 4b, 4c). The pulp is dead or dying – no question – and you are going to do root canal therapy. But what are you going to encounter after you enter the pulp chamber? Three or four canals in an upper molar? Are there hidden curvatures? Is there unusual anatomy that must typically



**Figure 4a:** The patient presented with an irreversibly inflamed pulp in tooth #3, confirmed by cold and heat testing (prolonged responses). Conventional radiographs revealed mesio-buccal root anatomy that was very curved, with the disto-buccal and palatal root anatomy appearing fairly straight

**Figure 4b:** Accutomo CT imaging allowed me to know pretty much all the anatomic information that was pertinent to treatment before I even cut the access cavity. The first important data point was that this tooth had only three canals (see axial view, top-left), saving a lot of time and allowing more conservative treatment. The second, although seen on the conventional radiograph, was that the curvature of the mesio-buccal canal was truly awe-inspiring (buccal view, lower left). The third piece of information saved my self respect and the patient's tooth from a broken rotary file, it revealed a severe disto-buccal canal curvature – in the normally hidden buccal plane (mesial view of DB root-lower right)

**Figure 4c:** Treatment, as a result, was quick and sure. The DB canal, despite the severe apical curvature was shaped with a single 20-06 GTX File. The MB canal required three GTX Files (ending at a 30-06) due to its severe multi-planar curvature. The palatal canal was shaped with a single 30-08 GTX file

**Figure 3a:** The patient presented with an irreversibly inflamed pulp in tooth #2, confirmed by prolonged thermal responses to cold and heat.

Conventional radiographs revealed a fused root structure with little or no information about the root canal anatomy

**Figure 3b:** Accutomo imaging revealed that this molar had only three canals (reassuring), and that the two buccal canals merged in the apical third and bifurcated again

**Figure 3c:** The post-operative conventional radiograph shows this anatomy treated out, with pre-informed anatomic knowledge (no looking for a fourth canal, knowing that the buccal canal merge apically – very unusual – and with adequate time committed to the irrigation process that allowed a three-dimensional obturation of the apical bifurcation of the canal system after the confluence

be encountered, step-by-step like a murder-mystery case?

I have finally come to understand, to my embarrassment, that there are no cases (with the given that I have one of these machines in my office) in which I will not diagnose better, treatment plan better, and treat better if I have all the information available to me that 3D volumetric imaging data can provide.

When I know beforehand that there are only three canals in an upper molar (most of them have four canals) I do not have to spend 20 minutes looking for a fourth canal, risking perforation, and being left with a sense of concern that it may have been there but I couldn't find it. When there are more canals than usual, I know ahead of time that they are present and where they are. I can find them by design rather than by skill and luck. When I see, pre-operatively, that there are accessory canals I am empowered to pursue irrigation strategies that are more likely to clean them out so I can fill them by intention.

With high-resolution CBCT imaging, I can deliver predictable success, meaning that I don't have to treat loser teeth with poor prognoses, and I can prosecute a treatment plan that is determined at the outset, rather than one that is made up during the procedure.

The tipping point for me was one year into my experience with this machine in my office (again, this is a bit embarrassing for me). Minimal radiation, high resolution imaging, definitive predictable treatment planning... I finally realized that I do not want to ever treat another endodontic case without all the information that I could have. Kind of like the question of why would

I ever treat a root canal without an operating microscope again. The answer is that I would not. 🦷

## References

- Brown D, Herbranson E (2009) 'Tooth Atlas 5.1 Demonstration Video', n.d., <<http://www.ehuman.com/education/tooth-atlas-5-1-demo>> (29 January 2009)
- Buchanan LS (1995) *Endodontic Success and Failure: Anatomy as a Rationale for Treatment*. DVD (with the first CT reconstructions of endodontic anatomy). Dental Education Laboratories
- Cohenca N, Simon JH, Roges R, Morag Y, Malfaz JM (2007) Clinical indications for digital imaging in dento-alveolar trauma. Part 1: traumatic injuries. *Dent Traumatol* 3: 95-104
- Estrela C, Bueno MR, Leles CR, Azevedo B, Azevedo JR (2008) Accuracy of cone beam computed tomography and panoramic and periapical radiography for detection of apical periodontitis. *J Endod* 34: 273-9
- Hess W (1925) *Anatomy of the root canal of teeth at the permanent dentition*. London, J. Bale, sons & Danielsson, ltd.
- Schilder H (1967) Filling root canals in three dimensions *Dent Clin North Am* 723-744
- Ziegler CM, Woertche R, Brief J, Hassfeld S (2002) Clinical indications for digital volume tomography in oral and maxillofacial surgery *Dentomaxillofac Radiol* 31: 126-30